



## MS AKT Practice Paper 2

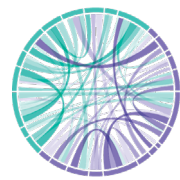A suite of practice papers is available to help medical students prepare for the UK Medical School Applied Knowledge Test (MS AKT). Please note that while this practice paper reflects the style and type of questions that students will encounter in the MS AKT, it is not blueprinted to the MLA Content Map.

This practice paper comes with and without the answer options.

We would like to recognise the contribution of medical schools, and members of the AKT working groups in particular, for their help in preparing these which we hope students will find a valuable resource.

Please note the practice papers are reviewed on an annual basis and updated accordingly. Items that may have appeared in earlier versions may now have been retired as part of this exercise. Should you have any questions about the clinical content of the practice exam please speak to the Assessment Lead in your school in the first instance.

**Any redistribution or reproduction of part or all of the contents in any form is prohibited other than for personal, educational and non-commercial use.**



- 1.** A 73 year old man collapses on the surgical ward 24 hours after having a sigmoid volvulus reduced by sigmoidoscopy.

He has no pulse.

ECG shows asystole.

Chest compressions and ventilation are started. The cardiac arrest team are with the patient.

What is the most appropriate next step in management?

- A.** Cardiac defibrillation
- B.** Intravenous 0.9% sodium chloride
- C.** Intravenous adrenaline/epinephrine
- D.** Intravenous atropine
- E.** Transcutaneous pacing

- 2.** A 78 year old woman has pain in both shoulders, hips and thighs. She is very stiff on waking in the morning and takes 2–3 hours to loosen up. She finds getting dressed difficult.

Investigations:

Erythrocyte sedimentation rate 67 mm/hr (<20)

CRP 87 mg/L (<5)

What is the most appropriate initial treatment?

- A.** Co-codamol
- B.** Leflunomide
- C.** Methotrexate
- D.** Naproxen
- E.** Prednisolone



3. A 36 year old man is rescued from a house fire. He is alert and talking but has a dull headache.

His pulse is 98 bpm, BP 139/86 mmHg, respiratory rate 22 breaths per minute and oxygen saturation 100% breathing 15 L/min oxygen via a non-rebreather mask.

What is the most appropriate investigation?

- A. Bicarbonate
- B. Carboxyhaemoglobin
- C. Haemoglobin
- D. Lactate
- E. Methaemoglobin

4. A 60 year old man has 2 days of a swollen, painful right leg. He has hypertension and takes ramipril. He is otherwise well.

He has a swollen right leg. The remainder of the examination is normal.

Investigations:

Haemoglobin	140 g/L	(130–175)
White cell count	$8.0 \times 10^9/\text{L}$	(3.8–10.0)
Platelets	$340 \times 10^9/\text{L}$	(150–400)

Creatinine	94 $\mu\text{mol/L}$	(60–120)
Calcium	2.5 mmol/L	(2.2–2.6)

ALT	30 IU/L	(10–50)
ALP	99 IU/L	(25–115)

APTT	30 seconds	(22–41)
PT	12 seconds	(10–12)

Urinalysis: normal

Chest X-ray: normal

Venous duplex ultrasound scan: thrombus in superficial femoral vein

What is the most appropriate additional investigation?

- A. No further investigation
- B. Carcinoembryonic antigen
- C. Prostate specific antigen
- D. Protein electrophoresis
- E. Ultrasound scan of abdomen



- 5.** A 65 year old woman underwent mechanical aortic valve replacement and coronary revascularisation 3 days ago. She takes aspirin long term.

She is being treated with dalteparin sodium.

What is the most appropriate long-term management?

- A.** Apixaban
- B.** Clopidogrel
- C.** Continue dalteparin
- D.** Rivaroxaban
- E.** Warfarin

- 6.** In order to assess the association between maternal smoking during pregnancy and low birthweight, smoking histories can be obtained from pregnant women at the first prenatal visit and data analysed by measuring birthweight at delivery.

What is the best description of this type of study?

- A.** Case-control
- B.** Cross-sectional
- C.** Prospective cohort
- D.** Randomised clinical trial
- E.** Retrospective cohort



- 7.** An 18 year old woman has had a chronic skin condition for several years. She describes having well-defined areas of scale formation at the sites of minor skin injuries, such as scratches or insect bites, typically when the injuries are healing. The scaling can persist for several weeks or months.

What is the most likely underlying skin condition?

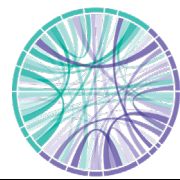- A.** Acne vulgaris
- B.** Eczema
- C.** Psoriasis
- D.** Seborrhoeic dermatitis
- E.** Vitiligo

- 8.** A 64 year old man has vomiting and severe chest pain after eating a large meal.

His temperature is 37.6°C, pulse 130 bpm, BP 95/50 mmHg and respiratory rate 30 breaths per minute. There is palpable subcutaneous emphysema on the left side of his neck.

What is the most likely diagnosis?

- A.** Diaphragmatic rupture
- B.** Mallory–Weiss tear
- C.** Necrotising fasciitis
- D.** Oesophageal rupture
- E.** Spontaneous pneumohaemothorax



- 9.** A 54 year old woman has polyuria and the feeling that she needs to drink continuously. She drinks at least 1 litre of water before bedtime and gets up three to four times during the night to pass urine. She has another glass of water each time that she gets up.

Investigations:

Sodium	140 mmol/L	(135–146)
Potassium	4.1 mmol/L	(3.5–5.3)
Urea	4.5 mmol/L	(2.5–7.8)
Creatinine	86 $\mu$ mol/L	(60–120)
Calcium (adjusted)	2.56 mmol/L	(2.2–2.6)
Fasting glucose	4.8 mmol/L	(3.0–6.0)
Serum osmolality	295 mOsmol/kg	(275–295)
Urinary osmolality	86 mOsmol/kg	(350–1000)

After 8 hours of a water deprivation test, serum osmolality is 308 mOsmol/kg and urinary osmolality is 152 mOsmol/kg.

Following the administration of desmopressin, serum osmolality is 286 mOsmol/kg and urinary osmolality is 660 mOsmol/kg.

What is the most appropriate next investigation?

- A.** CT scan of thorax, abdomen and pelvis
- B.** MR scan of pituitary
- C.** Oral glucose tolerance test
- D.** Technetium-99 Sestamibi parathyroid scan
- E.** Supervised fluid restriction and daily weights

- 10.** A 30 year old woman has irregular periods, decreased libido and galactorrhoea.

Visual field examination is normal.

Investigations:

Prolactin 5000 mU/L (100–500)

Pregnancy test: negative

MR scan of pituitary shows a 4 mm mass in the sella turcica.

What is the most appropriate management?

- A.** Cabergoline
- B.** Dexamethasone
- C.** Octreotide
- D.** Radiotherapy
- E.** Transsphenoidal surgery



- 11.** A 23 year old man is diagnosed with appendicitis. He is being prepared for theatre on the acute surgical ward. He has been vomiting intermittently all day, despite not having eaten for 24 hours.

The anaesthetist advises using an airway device to protect the lungs from regurgitated stomach contents.

Which airway device is most appropriate?

- A.** Guedel (oral) airway
- B.** i-gel® (supraglottic) airway
- C.** Laryngeal mask airway
- D.** Nasopharyngeal airway
- E.** Tracheal tube

- 12.** A 32 year old man is referred to a gastroenterology clinic with hepatomegaly. He has type 2 diabetes that is diet controlled. He takes no regular medication. He does not smoke. He drinks 16 units of alcohol per week.

Cardiovascular and respiratory examinations are normal. His abdomen is soft, with a 3 cm palpable liver edge. His BMI is 23 kg/m<sup>2</sup>(18–25).

Investigations:

Albumin	38 g/L	(35–50)
ALT	90 IU/L	(10–50)
ALP	112 IU/L	(25–115)
Bilirubin	15 µmol/L	(<21)

Ferritin	710 µg/L	(23–540)
CRP	6 mg/L	(<5)

What is the most appropriate next investigation?

- A.** Hepatitis C serology
- B.** Liver biopsy
- C.** Reticulocyte count
- D.** Serum γGT
- E.** Transferrin saturation



**13.** A 30 year old woman has severe headache 24 hours after a spinal anaesthetic.

Her temperature is 37.1°C, pulse 90 bpm and BP 120/80 mmHg.

What is the most likely diagnosis?

- A.** Low pressure headache
- B.** Meningitis
- C.** Migraine
- D.** Subarachnoid haemorrhage
- E.** Subdural haemorrhage

**14.** A 27 year old man develops a dry cough and left-sided chest pain of sudden onset. The pain is worse on taking a deep breath and coughing.

His temperature is 36.8°C, pulse 126 bpm, BP 108/60 mmHg, respiratory rate 28 breaths per minute and oxygen saturation 94% breathing air.

Investigations: ECG: sinus tachycardia

What is the most appropriate next investigation?

- A.** Chest X-ray
- B.** CTPA
- C.** D dimer
- D.** Echocardiography
- E.** V/Q scan





- 15.** A 23 year old man is scheduled to undergo an elective arthroscopy of his knee. He is to have a general anaesthetic for the operation.

The pre-operative assessment nurse advises him how long he needs to fast beforehand.

What fasting times for clear liquids and solids are most likely advised?

- A.** 2 hours for both clear liquids and solids
- B.** 2 hours for clear liquids, 6 hours for solids
- C.** 2 hours for clear liquids, 12 hours for solids
- D.** 6 hours for both clear liquids and solids
- E.** 6 hours for clear liquids, 12 hours for solids

- 16.** A 28 year old woman has a lump that she noticed incidentally when rubbing her neck.

There is a smooth, non-tender 1.5 cm mobile lump within the thyroid gland.

Investigations:

TSH	2.3 mU/L	(0.3–4.2)
Free T4	17 pmol/L	(9–25)

What is the most appropriate next investigation?

- A.** CT scan of neck
- B.** No further investigation needed
- C.** Thyroid antibodies
- D.** Thyroid scintigraphy
- E.** US scan of neck



- 17.** A 78 year old man has type 2 diabetes. His clinician does not invite him to join an internet-based self-monitoring programme because they consider him to be too old to engage with it effectively.

What is the most appropriate description of the clinician's approach?

- A.** Bias
- B.** Discrimination
- C.** Inequity
- D.** Prejudice
- E.** Stereotyping

- 18.** A 47 year old man with well controlled hypertension for many years attends for annual review. He takes ramipril (10 mg once daily).

His BP is 138/78 mmHg.

Investigations:

Sodium	139 mmol/L	(135–146)
Potassium	6.2 mmol/L	(3.5–5.3)
Urea	5.0 mmol/L	(2.5–7.8)
Creatinine	90 µmol/L	(60–120)

Which is the most appropriate immediate action?

- A.** Add indapamide
- B.** Advise low potassium diet
- C.** Change ramipril to amlodipine
- D.** Reduce dose of ramipril
- E.** Repeat urea and electrolytes



- 19.** A 33 year old woman has 4 months of joint pain and stiffness, predominantly affecting her feet. This is worst in the morning and gradually improves through the day. She feels tired all the time but reports no other health problems.

What investigation would confirm the most likely diagnosis?

- A.** Anti-cyclic citrullinated peptide antibodies
- B.** Anti-double-stranded DNA antibodies
- C.** Antinuclear antibody
- D.** CRP
- E.** Rheumatoid factor

- 20.** A 27 year old man has severe central chest pain. He admits to using cocaine shortly before the onset of the chest pain, but says that he had used it on only two previous occasions.

He is distressed and sweating. His pulse is 115 bpm and BP 118/68 mmHg.

An ECG shows sinus tachycardia with ST elevation in the lateral leads, and several ventricular ectopics.

What is the most likely mechanism by which cocaine has caused this acute episode?

- A.** Blockade of myocyte repolarisation
- B.** Coronary artery spasm
- C.** Enhanced platelet aggregation
- D.** Increased systemic vascular resistance
- E.** Rupture of pre-existing arterial plaques



- 21.** An 18 year old man, who was born in the UK, develops drowsiness and confusion 2 days after returning from visiting his grandparents in Malawi. Over the past week he has had recurrent episodes of high fever.

Investigations:

Haemoglobin      92 g/L      (130–175)

White cell count    $3.2 \times 10^9/L$    (4.0-11.0)

Platelets           $184 \times 10^9/L$    (150–400)

Blood film          parasites visible

Which is the most likely causative organism?

- A. *Plasmodium falciparum*
- B. *Plasmodium malariae*
- C. *Plasmodium vivax*
- D. *Trypanosoma brucei*
- E. *Trypanosoma cruzi*

- 22.** A 31 year old man has a painless lump in his scrotum.

There is a well-defined, non-tender spherical 1 cm mass on the right side of the scrotum. It is superior to the testis and transilluminates.

What is the most likely diagnosis?

- A. Abscess
- B. Epididymal cyst
- C. Hydrocoele
- D. Inguinal hernia
- E. Testicular tumour



**23.** A 68 year old man has 3 days of worsening vomiting and abdominal pain. He has not passed any stool for 3 days. Six months ago he underwent a right hemicolectomy for Dukes' A (T1, N0) bowel cancer.

He is dehydrated and his abdomen is distended.

What is the most likely diagnosis?

- A.** Adhesional small bowel obstruction
- B.** Anastomotic leak
- C.** Cholecystitis
- D.** Pancreatitis
- E.** Tumour recurrence

**24.** A 78 year old man is admitted with chronic oropharyngeal dysphagia. He has left ventricular systolic dysfunction (HFrEF). He is breathless on exertion, particularly when climbing stairs.

He weighs 70 kg. His pulse is 72 bpm and BP 132/80 mmHg.

He is being prepared for a percutaneous endoscopic gastrostomy feeding tube. The passage of a nasogastric tube has been unsuccessful, and he is having nil by mouth.

Which is the most appropriate volume of maintenance fluids (in mL) to prescribe for the next 24 hours?

- A.** 1750
- B.** 2450
- C.** 2800
- D.** 3000
- E.** 3250



- 25.** A 75 year old woman is reviewed 4 days after a fractured neck of femur repair. She has been agitated and upset, particularly at night. She has punched nurses and keeps trying to leave the ward. She has seen strange men in black capes entering the ward and believes that they are controlling the hospital. When she was seen in the memory clinic 6 months ago, she was found to have mild cognitive impairment.

What is the most appropriate treatment?

- A.** Chlordiazepoxide
- B.** Chlorpromazine
- C.** Donepezil
- D.** Haloperidol
- E.** Memantine

- 26.** A 72 year old woman has 6 months of increasing pain at the base of her right thumb. She is having difficulty opening jars and sewing. She is otherwise well. No other joints are painful. She is taking regular analgesia.

The first carpometacarpal joint is swollen and tender, with reduced opposition of the thumb.

What is the most likely diagnosis?

- A.** De Quervain tenosynovitis
- B.** Gout
- C.** Osteoarthritis
- D.** Rheumatoid arthritis
- E.** Septic arthritis



**27.** A 62 year old man has acute breathlessness with a weak cough, following a recent viral upper respiratory infection. Over the past 4 months, he has had double vision, limb weakness and slurred speech when tired.

His respiratory rate is 18 breaths per minute and oxygen saturation 96% breathing air. He is sweating and using his accessory muscles of inspiration.

What is the most appropriate test to monitor his respiratory function?

- A.** Arterial blood gas
- B.** FEV1
- C.** FVC
- D.** Peak expiratory flow rate
- E.** Ratio of FEV1 to FVC

**28.** A 40 year old man has 4 days of left flank pain associated with fever, nausea and vomiting.

His temperature is 39.6°C, pulse 118 bpm and BP 90/40 mmHg.

Imaging shows an obstructing proximal left ureteric stone with severe hydronephrosis.

He is treated with intravenous antibiotics and intravenous fluids.

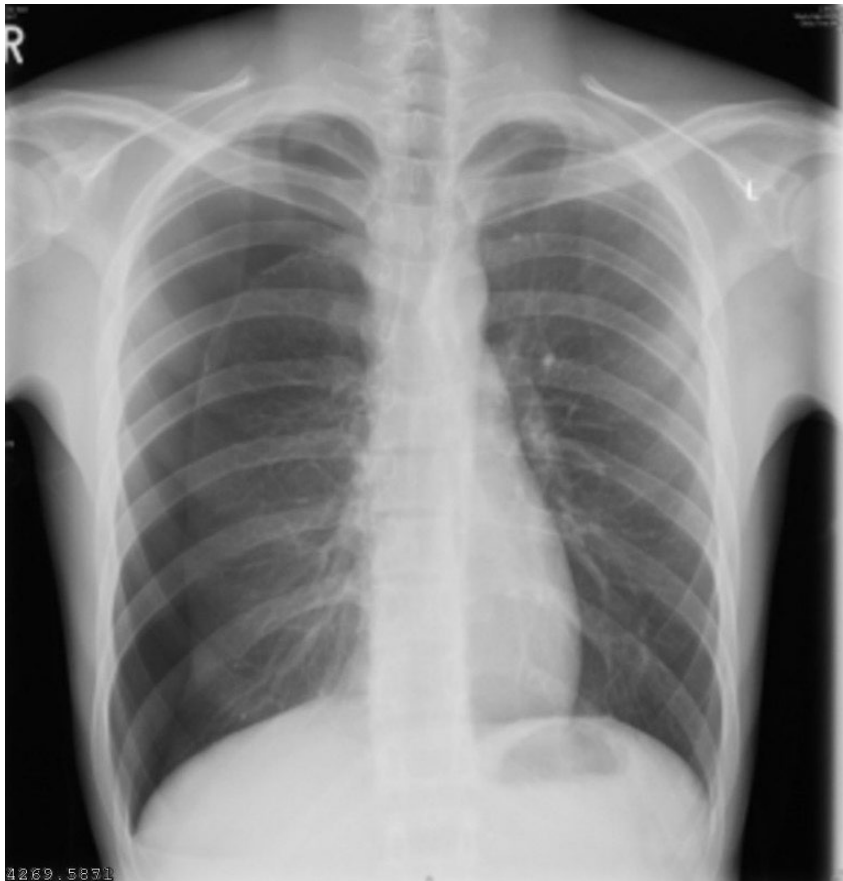
What is the most appropriate next step in management?

- A.** Lithotripsy
- B.** Nephrostomy
- C.** Retrograde pyelography
- D.** Ureteric stent
- E.** Urethral catheter



- 29.** A 19 year old man has had right-sided chest pain and breathlessness on exertion for 2 days. He smokes cannabis and takes cocaine.

His temperature is 36.4°C, pulse 108 bpm, BP 112/80 mmHg, respiratory rate 24 breaths per minute and oxygen saturation 94% breathing air. His trachea is central. He has reduced breath sounds at the right apex.



What is the most likely diagnosis?

- A.** Acute coronary syndrome
- B.** Coronary artery spasm
- C.** Pneumonia
- D.** Pneumothorax
- E.** Pulmonary embolism





**30.** An 80 year old woman attends the emergency department after being found collapsed at home. She has central chest pain.

Her pulse is 30 bpm, BP 70/40 mmHg and respiratory rate 26 breaths per minute.

Her 12-lead ECG shows sinus bradycardia with no evidence of myocardial ischaemia.

What is the most appropriate initial treatment?

- A.** Adrenaline/epinephrine
- B.** Atropine
- C.** Dobutamine
- D.** Normal saline
- E.** Permanent cardiac pacemaker

**31.** A 62 year old man develops acute pain, redness, swelling and warmth of his right first metatarsophalangeal joint. He has gout and hypertension. His medications are allopurinol, amlodipine and ramipril.

His eGFR is  $>60 \text{ mL/min/1.73 m}^2 (>60)$ .

What is the most appropriate next step in his management?

- A.** Change allopurinol to febuxostat
- B.** Start naproxen
- C.** Stop allopurinol
- D.** Stop amlodipine
- E.** Stop ramipril



- 32.** A 10 year old boy has deafness of new onset. He has had a recent respiratory tract infection.

When the tuning fork is placed in the middle of his forehead he hears the tone loudest in his right ear. When the tuning fork is placed on the bone behind the right ear the sound is louder than when it is held in front of his right external auditory meatus. When the tuning fork is held in front of the left external auditory meatus the sound is louder than when it is placed on the bone behind the same ear.

What type of hearing loss is this?

- A.** Bilateral mixed deafness
- B.** Left conductive deafness
- C.** Left sensorineural deafness
- D.** Right conductive deafness
- E.** Right sensorineural deafness

- 33.** A 55 year old man has had painful red swelling of his left lower leg for 2 days. He has type 2 diabetes mellitus and takes metformin.

His temperature is 37.6°C. He has a tender erythematous area extending from the ankle to the proximal calf.

What is the most likely causative organism?

- A.** Bacteroides species
- B.** Proteus mirabilis
- C.** Pseudomonas aeruginosa
- D.** Staphylococcus epidermidis
- E.** Streptococcus pyogenes



- 34.** A 64 year old woman is due to undergo an arthroscopy of her knee. She has type 2 diabetes and takes metformin (500 mg twice daily) and gliclazide (80 mg each morning).

Her glycated haemoglobin (HbA1c) is 54 mmol/mol (20–42).

She is scheduled first on tomorrow morning's day case list and is asked to fast from midnight tonight.

What is the most appropriate plan for managing her diabetic medication?

- A.** Continue both drugs and start a variable-rate insulin infusion
- B.** No change to usual medication
- C.** Omit both drugs and start a variable-rate insulin infusion
- D.** Omit gliclazide and continue metformin
- E.** Omit metformin and continue gliclazide

- 35.** A 67 year old man has difficulty walking. He states that he has to raise his left leg higher in the air than normal to avoid scraping his toes on the ground when he walks.

When he raises the left foot from the floor, the ankle assumes a plantar-flexed position with the toes directed towards the floor.

Which nerve is most likely to be affected?

- A.** Common peroneal
- B.** Medial plantar
- C.** Saphenous
- D.** Superficial peroneal
- E.** Tibial



**36.** A 35 year old woman has 6 months of cyclical pain in both breasts. She has recently noticed a lump in the right breast.

There is diffuse nodularity of the axillary tails of both breasts with a discrete 20 mm mass in the upper outer quadrant of the right breast.

Fine needle aspiration is performed and 5 mL of brown fluid is removed, with disappearance of the mass.

Cytology shows cellular debris with no malignant cells.

What is the most likely diagnosis?

- A.** Breast abscess
- B.** Breast carcinoma
- C.** Fat necrosis
- D.** Fibroadenoma
- E.** Fibrocystic disease

**37.** A 70 year old man has a brief episode of twitching that starts in his left hand and spreads up the arm over 2 minutes, then stops. His arm feels weak for an hour afterwards. He had an ischaemic stroke affecting his left side 6 months ago with good functional recovery. He has type 2 diabetes mellitus and is taking clopidogrel, metformin, ramipril and atorvastatin. He is anxious about a further stroke.

There is no weakness on neurological examination.

What is the most likely diagnosis?

- A.** Dissociative (non-epileptic) seizure
- B.** Focal seizure
- C.** Hypoglycaemic episode
- D.** Migraine
- E.** Transient ischaemic attack



**38.** A 63 year old woman has 4 months of abdominal bloating, fatigue and nausea.

She is found to have ovarian cancer.

Staging CT is performed to look for lymphatic spread and metastatic disease.

Where is her tumour most likely to spread initially?

- A.** Deep inguinal nodes
- B.** External iliac nodes
- C.** Internal iliac nodes
- D.** Para-aortic nodes
- E.** Superficial inguinal nodes

**39.** A 52 year old woman has had three episodes of severe epigastric pain associated with vomiting over the past 3 months. The episodes occurred following eating and lasted for about 1 hour. She has type 2 diabetes mellitus and takes metformin.

Abdominal examination is normal. Her BMI is 35 kg/m<sup>2</sup>(18–25).

Investigations:

ALT	15 IU/L	(10–50)
ALP	71 IU/L	(25–115)
Bilirubin	9 µmol/L	(<21)

Ultrasound scan of abdomen: single 2 cm gallstone in gallbladder, common bile duct normal, evidence of fatty liver.

What is the most appropriate management?

- A.** Endoscopic retrograde cholangiopancreatography
- B.** Laparoscopic cholecystectomy
- C.** MR cholangiopancreatography
- D.** Open cholecystectomy
- E.** Ursodeoxycholic acid



**40.** A 56 year old woman develops vertigo, nausea, vomiting and intense occipital headache of sudden onset. She is unable to walk without falling. She has hypertension and takes ramipril.

Her temperature is 37.4°C, pulse 94 bpm, BP 146/92 mmHg, respiratory rate 12 breaths per minute and oxygen saturation 96% breathing air. She has multidirectional nystagmus and some clumsiness of her right arm.

What is the most likely diagnosis?

- A. Acute labyrinthitis
- B. Benign paroxysmal positional vertigo
- C. Cerebellar stroke
- D. Ménière disease
- E. Multiple sclerosis

**41.** A 79 year old woman has 3 months of a left leg venous ulcer that is slowly healing.

Ankle–brachial pressure indices are 0.9 on the left side and 1.1 on the right side (0.8–1.2).

What is the most appropriate management?

- A. Diagnostic biopsy
- B. Full-length graduated compression bandaging
- C. Intermittent pneumatic compression therapy
- D. No further management required
- E. Repeat ankle–brachial pressure indices in 3 months



**42.** A 26 year old woman sustains a head injury in a motorcycle accident.

Her eyes are closed, but she opens them when asked. She is confused about what happened and where she is, but attempts to talk about it. She repeatedly attempts to remove the cannula from her wrist.

What is her Glasgow Coma Score?

- A.** E1, V1, M1, total = 3
- B.** E2, V2, M3, total = 7
- C.** E3, V3, M3, total = 9
- D.** E3, V4, M5, total = 12
- E.** E4, V5, M5, total = 14

**43.** A 65 year old man has sudden pain and redness in his right eye. He also has a headache and nausea.

Visual acuity is 6/60 in the right eye. The eye is congested, with a hazy cornea and mid-dilated pupil.

What is the most likely diagnosis?

- A.** Acute glaucoma
- B.** Conjunctivitis
- C.** Corneal ulcer
- D.** Scleritis
- E.** Uveitis



**44.** A 68 year old man collapses when rising from a chair and is seen in the emergency department 45 minutes later. He has COPD and hypertension. He smokes 10 cigarettes per day.

He is conscious but has reduced strength in his left arm (3/5) and leg (4/5) and slurring of speech. He has bilateral scattered wheeze and bilateral carotid bruits on auscultation.

Which is the most appropriate initial radiological investigation?

- A. Cerebral angiography
- B. CT cerebral venogram
- C. CT scan of head
- D. MR scan of brain
- E. Ultrasound scan of carotid arteries

**45.** A 25 year old man sustains 40% full-thickness burns in a house fire. Despite intensive treatment, he becomes breathless and hypotensive. He develops a petechial rash.

His temperature is 38°C, pulse 110 bpm, BP 80/50 mmHg and oxygen saturation 96% breathing 40% oxygen.

Investigations:

Haemoglobin	110 g/L	(130–175)
White cell count	$4.2 \times 10^9/L$	(4.0–11.0)
Platelets	$15 \times 10^9/L$	(150–400)
APTT	75 seconds	(22–41)
PT	25 seconds	(10–12)
Fibrinogen	0.7 g/dL	(1.5–4.0)
Fibrinogen degradation products	137 mg/mL	(<8)

What is the most likely diagnosis?

- A. Anaphylactic reaction to antibiotics
- B. Disseminated intravascular coagulation
- C. Fat embolism
- D. Immune thrombocytopenic purpura
- E. Pulmonary embolism





- 46.** A 65 year old woman with newly diagnosed advanced lung cancer has 1 day of breathlessness and 1 week of progressive headache.

Her pulse is 88 bpm, respiratory rate 20 breaths per minute and oxygen saturation 95% breathing 4 L/min oxygen via nasal prongs. She has a swollen face and neck with distended veins on her chest. Her chest is clear.

CT scan of chest shows mediastinal lymphadenopathy compressing the superior vena cava.

What is the most appropriate initial treatment?

- A.** Alteplase
- B.** Dexamethasone
- C.** Heparin infusion
- D.** Insert endovascular stent
- E.** Mannitol

- 47.** A 65 year old man has 3 weeks of progressive ankle oedema. He has a lifelong history of heavy smoking and drinks 12 units of alcohol per week.

His BP is 125/85 mmHg and oxygen saturation 98% breathing air. He has marked bilateral pitting ankle oedema.

Investigations:

Creatinine	85 $\mu$ mol/L	(60–120)
Urinary protein: creatinine ratio	400 mg/mmol	(<30)
Fasting glucose	5.7 mmol/L	(3.0–6.0)
Total cholesterol	9 mmol/L	(<5.0)
Albumin	20 g/L	(35–50)

He is treated with furosemide.

What investigation is most likely to identify the cause?

- A.** Chest X-ray
- B.** Renal arteriography
- C.** Renal auto-antibody screen
- D.** Renal biopsy
- E.** Serum protein electrophoresis



**48.** A 55 year old woman has a tender, erythematous, swollen hard cord in the long saphenous vein distribution in her calf. The pain persists despite paracetamol. She has longstanding bilateral varicose veins.

An ultrasound scan shows superficial thrombophlebitis without deep vein thrombosis.

What is the most appropriate treatment?

- A.** Dipyridamole
- B.** Flucloxacillin
- C.** Gabapentin
- D.** Naproxen
- E.** Rivaroxaban